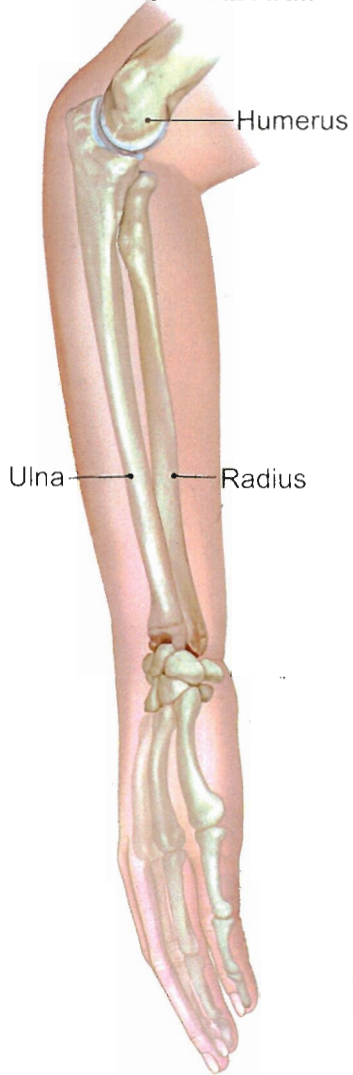


# Mr. Smith's Traumatic Left Arm Injury



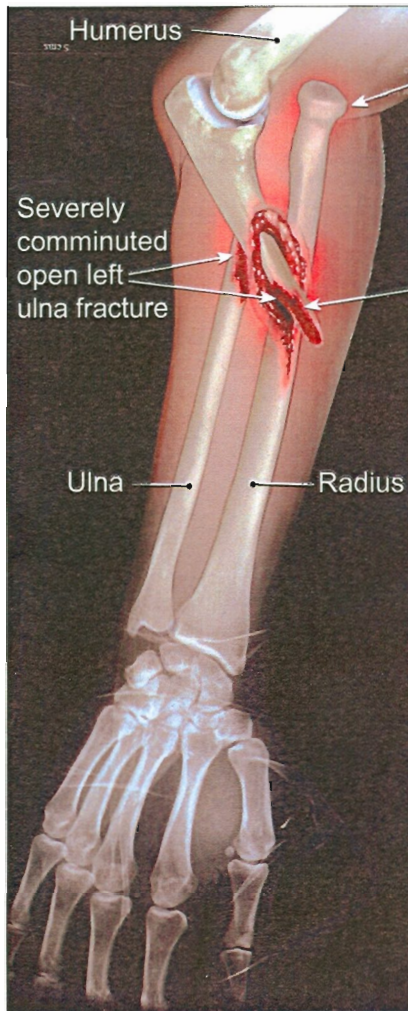
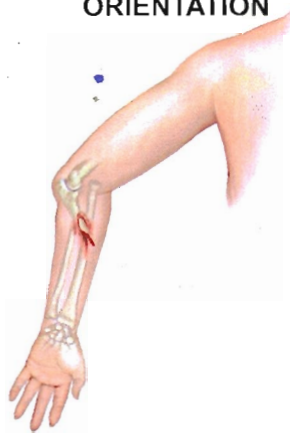**NORMAL ARM**



**NORMAL ORIENTATION (Back View)**



**INJURY ORIENTATION**



Anteriorly dislocated radial head

Ulnar fragments piercing through the open wound

**PRE-OPERATIVE X-RAY**

