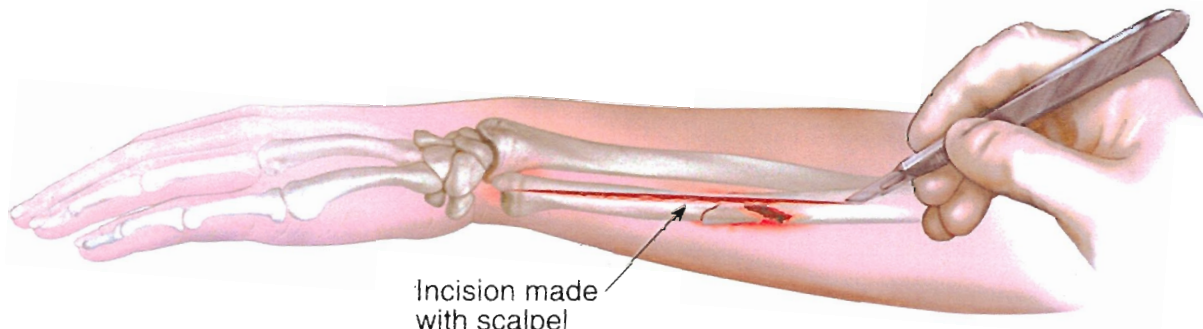
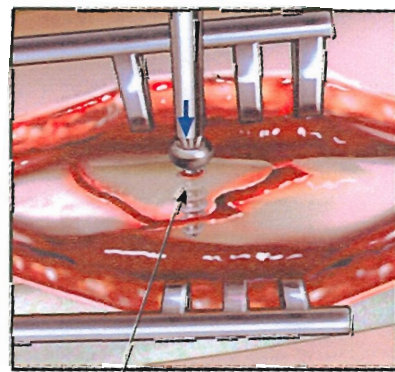


~~XXXXXXXXXXXX~~ Jan. 20, 2006

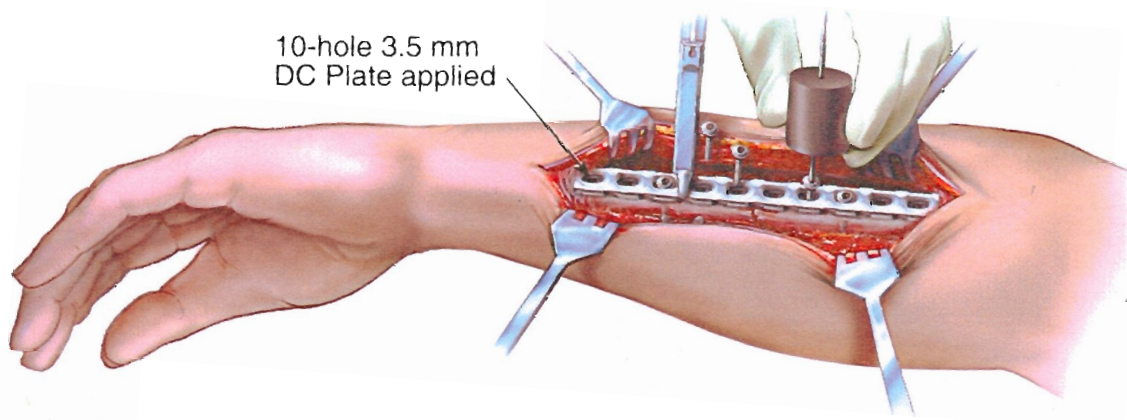
Left Arm Open Reduction and Internal Fixation Surgery



Incision made with scalpel



Large distal butterfly fragment fixated to the proximal ulna



10-hole 3.5 mm DC Plate applied

POST-OP JAN. 20, 2006 X-RAY (VOLAR VIEW)

