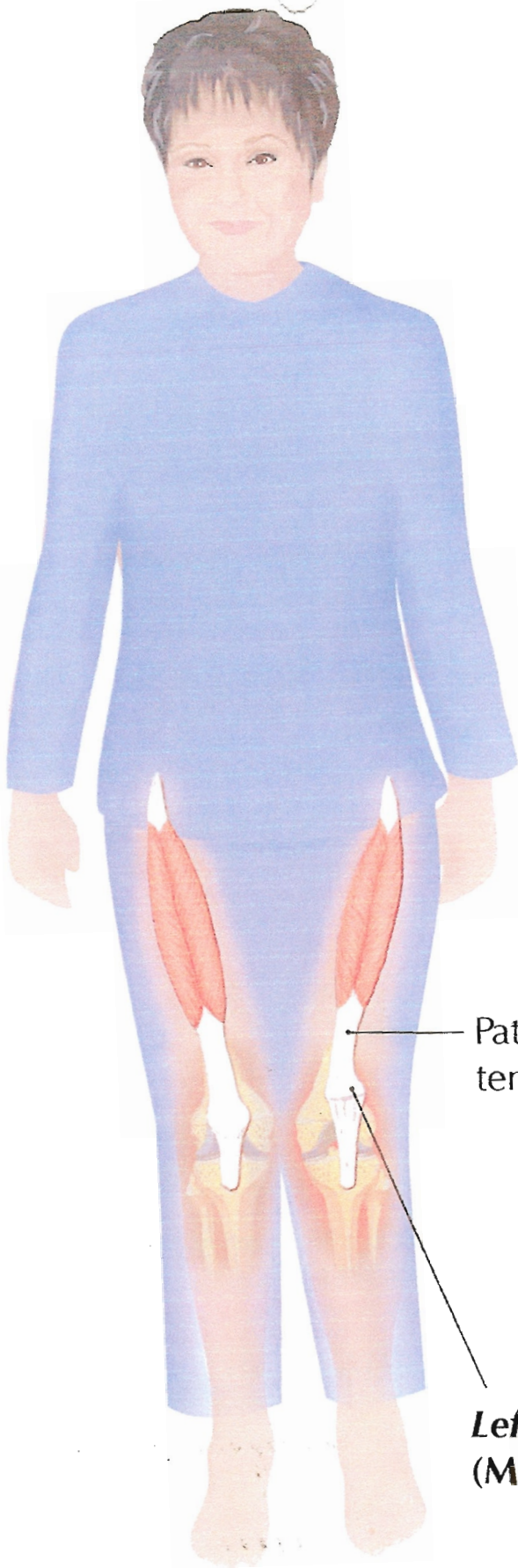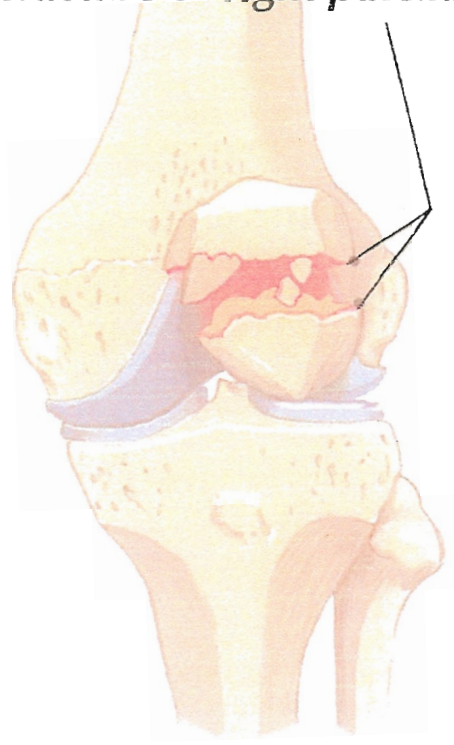


Patellar tendon

Left upper patellar fragment
(MRI dated October 18, 2006)

Comminuted transverse fracture of right patella



Dr. J. H. H. H.
August 31, 2005

⑤